

# Acute Cerebral Edema: A Lethal Neurological Complication in A Patient with COVID-19 Infection. Case Report and Literature Review

**M. Puodžiūnaitė\***

**R. Sadeckaitė\*\***

**A. Čikotienė\*\***

*\*Department of Family Medicine, Lithuanian University of Health Sciences, Lithuania*

*\*\*Therapy Clinic, Department of Neurology, Kaunas Hospital of Lithuanian University of Health Sciences, Lithuania*

**Summary.** *Introduction.* COVID-19 can damage the nervous system by direct viral damage to the neural cells or by immunopathology. More serious medical conditions such as cerebral edema, neuronal degeneration, encephalitis, acute disseminated encephalomyelitis, Guillain–Barré syndrome, Bickerstaff’s brainstem encephalitis, Miller-Fisher syndrome, polyneuritis, toxic encephalopathy, and stroke can occur.

*Case report.* We report a case of a 40-year-old patient with previous history of hypertension and no other chronic disease who was admitted to the hospital with respiratory distress due to SARS-CoV-2-induced bilateral pneumonia. A few days later, he developed worsening respiratory function with an acute seizure episode. Head CT scan revealed subarachnoid hemorrhage with diffuse cerebral edema as a lethal neurological complication, possibly secondary to COVID-19.

*Discussion.* COVID-19 induces CNS damage through various mechanisms including ACE-2 receptor damage, cytokine storm syndrome, secondary hypoxia, blood-brain barrier disruption, and neuroinflammation. Neurological symptoms correlate with the severity of COVID-19 disease and may range from asymptomatic infection to severe and lethal forms. Acute cerebral edema, as illustrated by our case, may result from a combination of diffuse endothelial dysfunction, cytokine release syndrome, and hypoxic damage from pulmonary dysfunction.

**Keywords:** SARS-CoV-2, COVID-19, neurological complications, cerebral edema.

## INTRODUCTION

The novel infection of coronavirus disease 2019 (COVID-19) caused by severe acute respiratory syndrome coronavirus 2 (SARS-CoV-2) began in December 2019 in China. The World Health Organization declared it a pandemic on March 11, 2020. More than 267 million people have been affected worldwide and more than 5 million have died by December 2021 [1]. There is increasing evidence of neurological complications in patients with COVID-19. The virus can damage the nervous system ei-

ther by direct viral damage to the neural cells or by immunopathology. Headache, nausea, vomiting, hyposmia, and hypogeusia are mild neurological symptoms. More serious medical conditions such as cerebral edema, neuronal degeneration, encephalitis, acute disseminated encephalomyelitis, Guillain–Barré syndrome, Bickerstaff’s brainstem encephalitis, Miller-Fisher syndrome, polyneuritis, toxic encephalopathy, and stroke can also occur [2, 3]. Understanding of the nervous system involvement patterns and neurologic manifestations can be helpful in improving the assessment and management of SARS-CoV-2 patients.

### Address:

*Rasa Sadeckaitė  
Therapy Clinic, Department of Neurology, Kaunas Hospital  
of Lithuanian University of Health Sciences, Lithuania  
Hipodromo St. 13, LT-47144 Kaunas  
E-mail: rasa.sadeckaitė@kaunoligonine.lt*

## CASE REPORT

A 40-year-old man was admitted to our emergency department. Despite the fact, that the patient was in good physical

© Neurologijos seminarai, 2022. Open Access. This article is distributed under the terms of the Creative Commons Attribution 4.0 International License CC-BY 4.0 (<http://creativecommons.org/licenses/by/4.0/>), which permits unrestricted use, distribution, and reproduction in any medium, provided you give appropriate credit to the original author(s) and the source, provide a link to the Creative Commons license, and indicate if changes were made.

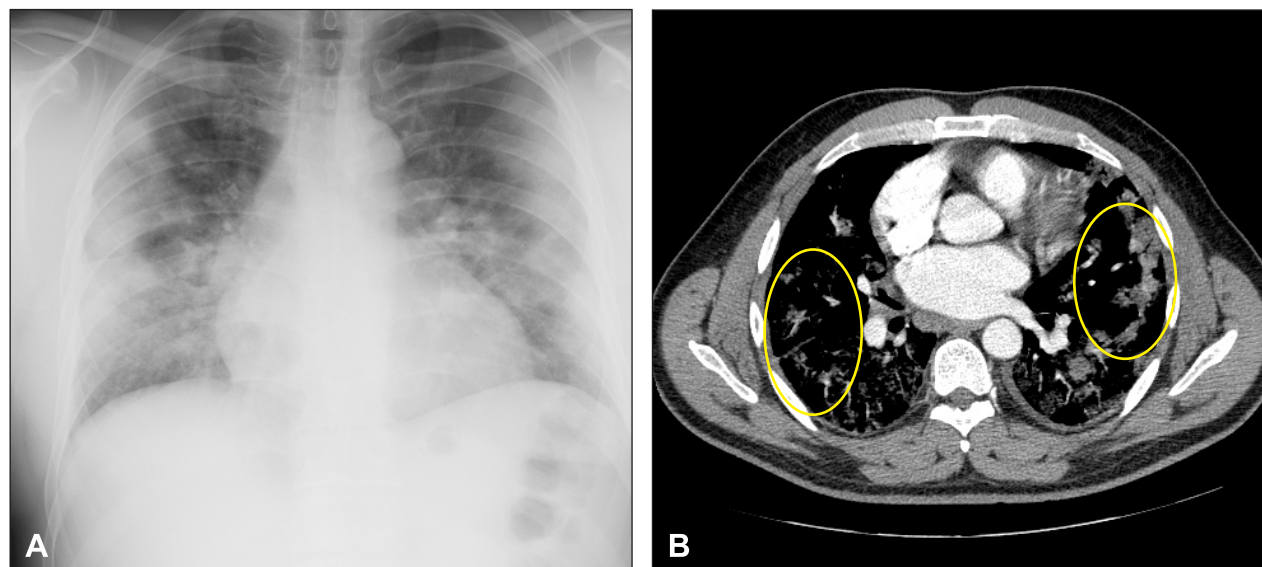


Fig. 1. Chest X-ray on admission demonstrates bilateral pulmonary infiltrates (A). Chest CT scan showing typical CT findings of COVID-19: bilateral peripheral ground-glass opacities in the lungs (B, circle).

shape and had a normal body mass index (BMI), he was diagnosed with primary arterial hypertension. The latter was effectively controlled with a fixed dose of angiotensin-converting enzyme inhibitor (ACEI) perindopril. The patient developed general fatigue, febrile fever, and cough. A couple of days later he tested positive for SARS-CoV-2 polymerase chain reaction in a nasopharyngeal swab test performed on the outpatient basis. The patient was not vaccinated and contracted the virus from one of his unvaccinated family members. Within a few days his symptoms deteriorated as his cough intensified and severe dyspnea presented. The ambulance took him to the emergency room as the patient developed acute respiratory distress syndrome (ARDS) with prominent tachypnea (the respiratory rate was approximately 22 times per minute) and desaturation ( $\text{SpO}_2$  was 86-88%). Oxygen therapy was administered using a non-rebreathing mask with oxygen flow rate of 10 L/min. Chest X-ray revealed bilateral infiltrates (Fig. 1A). Blood tests showed minor thrombocytopenia at  $102 \times 10^9/\text{L}$  (reference range:  $130-400 \times 10^9/\text{L}$ ) and increased inflammatory markers with CRP of 146.3 mg/L (reference range: 0-10 mg/L) and white-cell count of  $8.53 \times 10^9/\text{L}$  (reference range:  $4-10 \times 10^9/\text{L}$ ) with neutrophilia (80%). The neutrophil-to-lymphocyte ratio was 4. In addition, other prognostic markers were also poor with ferritin being as high as 1892.47 g/L (reference range: 30-400 g/L) and the lactate dehydrogenase (LDH) 702.86 g/L (reference range: 135-225 g/L). For further treatment, the patient was admitted to the Covid-19 unit of our hospital. The patient was treated with intravenous antibiotics (1.2 g of amoxiclav 3 times a day), dexamethasone (8 mg once a day given intravenously), and a prophylactic dose of nadroparin (5700 IU/0.6 ml given subcutaneously). As the patient had normal renal and liver function, the 5-day course of remdesivir was initiated. Inflammatory markers decreased with the course of antibiotics and anti-

viral treatment, however, the severity of respiratory distress progressed, thus oxygen demand increased sharply. Thereupon, the patient was started oxygen therapy through a re-breathing mask with a flow rate of 15 L/min. Arterial blood gas test depicted severe hypoxemia with  $\text{pO}_2$  of 54 mmHg and arterial saturation of 88%. Chest computed tomography (CT) was performed in suspicion of pulmonary embolism, but no filling defects were discovered. CT revealed a large extent of lung damage, as ground-glass opacities characteristic of COVID-19 were seen in around 80% of the lung tissue (Fig. 1B).

Suddenly, the medical staff found the patient in his ward experiencing a seizure episode. The latter was terminated by 10 mg of diazepam given intravenously. After the seizure episode, the patient remained unconscious, reacting to a painful stimulus by bending arms up, so the Glasgow Coma Scale (GCS) score at that moment was estimated to be 6 utmost (M-4, E-1, S-1). The pupils were equal in size, reactive to light. Increased muscle tone in the lower extremities and positive Babinski sign on both sides were also present. Urgent head CT scan was performed, which revealed signs of brain stagnation, diffuse cerebral edema, and subarachnoid hemorrhage (SAH) on both sides (Fig. 2). Due to the therapeutic condition, signs of brain stagnation, and loss of differentiation between white and grey matter, neurosurgeons did not recommend urgent surgery, therefore, conservative treatment of brain edema was recommended. Shortly after, the GCS score decreased to as low as 3 (M-1, E-1, S-1), and for further treatment, due to progressing cerebral edema and respiratory failure, the patient was admitted into intensive care unit (ICU) where he was immediately intubated. Brain stem reflexes on subsequent clinical neurological examination were absent. Given the infaust prognosis, further treatment was considered futile, and the patient died shortly afterwards.

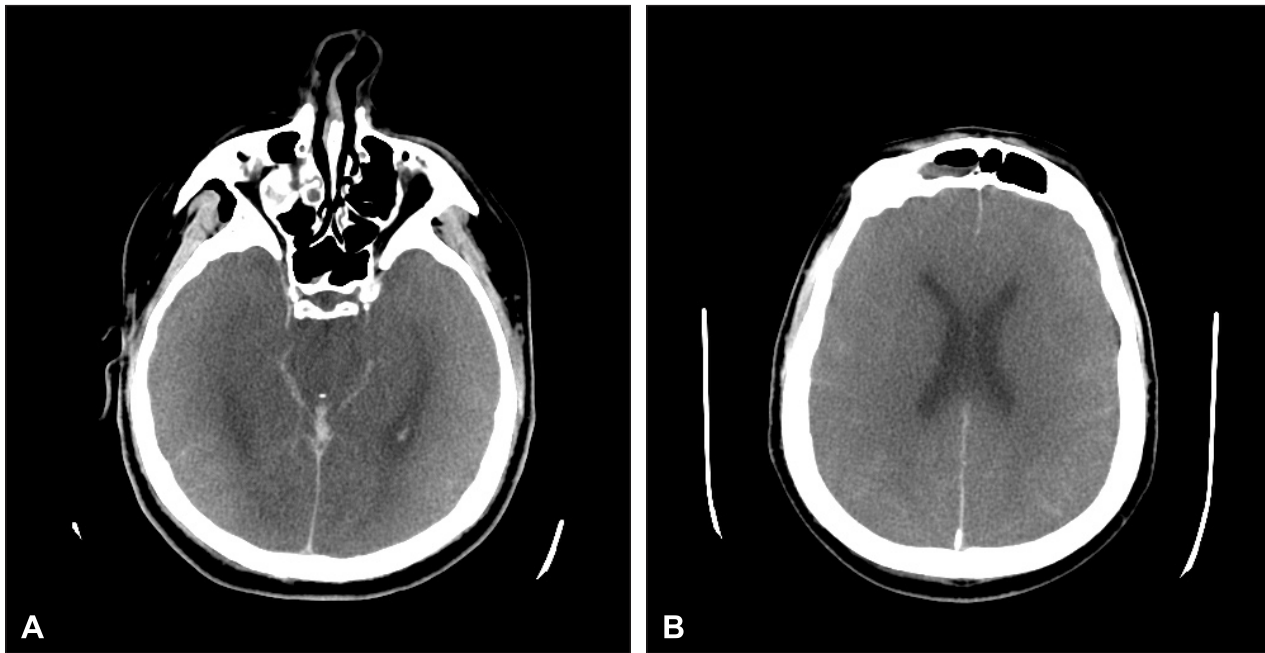


Fig. 2. Non contrast head CT scan demonstrates diffuse cerebral edema with subarachnoid hemorrhage (A and B).

## DISCUSSION

There are several different mechanisms involved in COVID-19-associated damage to the central nervous system (CNS), in particular activation of inflammatory and thrombotic pathways and a direct viral effect on the endothelium and the parenchyma. Around 40% of patients with COVID-19 develop neurological symptoms. Cerebral edema has been detected in autopsy studies of brain tissue of COVID-19 patients [4, 5]. Several identified risk factors predispose patients with COVID-19 for having neurological complications: patient age (severely ill patients were significantly older ( $58.2 \pm 15$  vs.  $48.9 \pm 14.7$  years) and comorbid conditions, especially hypertension (36.4% vs. 15.1%) [6].

The coronavirus uses angiotensin-converting enzyme 2 (ACE-2) receptors in the epithelial cells of the respiratory and gastrointestinal tract for penetration [7, 8]. The virus can enter the CNS by hematogenous dissemination (using endothelial ACE-2 receptors expressed in brain vessels or crossing a leaky blood-brain barrier (BBB) affected by systemically produced cytokines) or by neuronal

and olfactory pathways [1, 7, 9, 10]. Moreover, the high availability of ACE-2 receptors in the enterocytes cells of the gastrointestinal tract and the direct connection of the enteric nervous system with the brain via the afferent endings of the vagus nerve from the lungs provides an additional route for the virus to enter the brain [10].

The possible course of the COVID-19 disease can be divided into three “NeuroCovid Stages” based on the analysis of the potential pathophysiological mechanisms involved in neurological manifestations of SARS-Cov-2 (Table) [11].

Patients infected with COVID-19 may have a massive inflammatory reaction due to the rapid accumulation of T-cells and macrophages releasing cytokines into the bloodstream, which aim to destroy the virus, resulting in cytokine storm syndrome (CSS), characterized by increased IL-1, IL-2, IL-6, granulocyte-colony stimulating factor, interferon- inducible protein 10, macrophage inflammatory protein 1, and tumor necrosis factor (TNF)- [1, 12]. This hyperinflammatory response can manifest with high levels of C-reactive protein, coagulopathy (elevated D-dimer levels, low platelet count, and fibrinogen

Table. “NeuroCovid Stages”

Stage I	SARS-Cov-2 binding to ACE-2 receptors is limited to the nasal and gastrointestinal tract epithelial cells. The cytokine storm activated by the virus remains low and controlled. Patients may have only smell or taste impairments and often recover.
Stage II	SARS-Cov-2 activates a strong immune response with high levels of cytokines, which increase the levels of ferritin, C-reactive protein, D-dimer. The hypercoagulable state triggers the formation of blood clots. Immune response also causes vasculitis in muscles or CNS.
Stage III	SARS-Cov-2 cytokine storm damages the BBB and results in infiltration of inflammatory factors in the CNS. The resultant edema and brain injury lead to delirium, encephalopathy, and/or seizures. High titers of virus occupy a higher portion of ACE-2 and therefore levels of angiotensin II increase. Then, heightened peripheral vascular resistance and hypertension increase the risk of intracranial hemorrhage.

levels), tissue damage (elevated LDH and alanine aminotransferase and aspartate aminotransferase levels), macrophage/hepatocyte activation (elevated ferritin levels), and cytopenias (thrombocytopenia and lymphopenia) [1, 13]. Furthermore, immune dysregulation with hyperinflammatory response contribute to the damage of lymphocytes, especially T-lymphocytes, therefore an increased neutrophil-to-lymphocyte ratio may be present. These laboratory biomarkers are used to predict disease severity. In severe cases, the cytokine storm results in ARDS, characterized by a serious shortness of breath and hypoxemia, and is the principal cause of death [8, 14–16].

Based on the clinical symptoms and laboratory test results (high level of C-reactive protein, elevated D-dimer, LDH, ferritin levels, low platelet count), our patient had a severe form of COVID-19 infection with CSS. Acute clinical deterioration could be related to pathophysiological mechanisms described in “NeuroCovid Stage” III. Despite this, it remains unclear whether diffuse cerebral edema was the result of anoxia induced by severe viral lung damage (80% according to chest CT scan data) and cytokine storm, or another cause (primary SAH, vasculitis, or encephalitis) because cerebral CT angiography and lumbar puncture were not performed due to the poor overall condition of the patient: he developed respiratory failure, which required urgent intubation and ICU admission.

One of the potential mechanisms for neurological complications can be related to SARS-CoV-2-induced ARDS and hypoxia. Normal blood oxygen level is around 95%, and the brain may not receive sufficient oxygen if this level falls below 90% [10]. Diffuse alveolar damage in COVID-19 leads to impaired gas exchange by the respiratory system and to general hypoxia. Anaerobic metabolism in the mitochondria of brain cells results in acidosis. It causes BBB disruption which can contribute to CNS complications: intracerebral vasodilation, brain edema, obstruction of cerebral blood flow. As a result of continuous hypoxia, intracranial hypertension can appear [1, 4, 8]. This can cause a change in the level of consciousness and even coma. Brain edema is assumed to be secondary to the COVID-19-related cytokine storm, ARDS, and either leads to the seizure. In this case, severe hypoxic brain damage may explain rapid clinical deterioration of our patient. On the other hand, an acute seizure episode can result from meningeal irritation due to the CNS infection or SAH. According to several publications, SARS-CoV-2 binding to the ACE-2 receptor may raise blood pressure in the brain, enhance the permeability of BBB, and increase the risk of hemorrhage. Hypertension, especially with the presence of thrombocytopenia and bleeding disorders, is a factor that may contribute to cerebral hemorrhage in patients with COVID-19 [17–19]. In addition, critically ill patients with severe SARS-CoV-2 infection often show elevated levels of D-dimer and severe platelet reduction, which puts these patients at higher risk for acute cerebrovascular events [20]. COVID-19 has been associated with coagulopathies such as disseminated intravascular coagulation (DIC), thrombocytopenia, elevated D-dimer, and pro-

longed prothrombin time, which can result in hemorrhage [21]. In our case, the patient had a reduced platelet count, and this may be a factor predisposing bleeding complication.

Viral encephalitis and direct invasion of the virus to the CNS can cause seizures. The accumulation of inflammatory markers associated with SARS-CoV-2 infection, can cause a local cortical irritation that precipitates seizures [1, 5, 10, 14]. In critically ill COVID-19 patients, metabolic and electrolyte imbalances, ongoing hypoxia, and inflammatory/infectious processes may contribute to seizure [21]. Unfortunately, in our case, cerebrospinal fluid (CSF) analysis in order to exclude CNS infection was not performed due to severe brain edema and SAH. On the other hand, COVID-19 infection has been suggested as a cause of infectious toxic encephalopathy, also known as acute toxic encephalitis. It is a rare type of reversible brain dysfunction syndrome caused by factors such as systemic toxemia, metabolic disorders, and hypoxia during the process of acute infection and is associated with cerebral edema with no evidence of inflammation on CSF analysis. Patients with a mild form may develop headache, dysphoria, or delirium, while more severe forms may lead to disorientation, paralysis, loss of consciousness, and even coma [4, 5].

More recently, reversible cerebral vasoconstriction syndrome has been described as one of potential mechanism of CNS injury in COVID-19 patients. Endothelial dysfunction can result in microcirculatory vasoconstriction leading to posterior reversible encephalopathy syndrome (PRES). SARS-Cov-2 slows the conversion of angiotensin II to angiotensin. Higher levels of angiotensin II are associated with vasoconstriction and peripheral vascular resistance. PRES has been reported in 10 patients with COVID-19 from 8 studies and it usually presents with acute impairment of consciousness, headache, visual disturbance, and seizures. It is associated with cortical or subcortical vasogenic edema, involving predominantly the parietal and occipital regions bilaterally. In COVID-19, endothelial dysfunction in combination with hemodynamic instability and immunological activation with release of cytokines can increase the vascular permeability in the brain tissue. Disruption of BBB in these cases may cause vasogenic edema and PRES [21, 22].

Furthermore, SARS-CoV-2-induced decrease in ACE-2 activity can lead to vasoconstriction and dysfunction of cerebral autoregulation and, subsequently, blood pressure spikes, which can cause arterial wall rupture and hemorrhage [4, 21, 23–25]. Intracranial hemorrhage (including SAH) has been reported in 0.3–1.2% of patients with COVID-19 based on a review of 9 cohort studies (N=13,741 patients) [26]. In a retrospective study of 3,403 patients who were confirmed positive for SARS-CoV-2 infection, Sawlani et al. reported that neuroimaging showed abnormalities in 23% of patients: the most consistent neuroradiological finding was microhaemorrhage (60%) while SAH accounts for only 5% [27]. A potential mechanism for non-aneurysmal SAH

may be vasculitis involving the medium and small-sized arteries in the brain diagnosed by neuroimaging in patients with COVID-19 [28]. In another study, Büttner et al. retrospectively analyzed brain CT and magnetic resonance imaging (MRI) scans of 34 hospitalized COVID-19 patients. Pathological findings were detected in 38.2% of patients. The most common findings were microbleeds (20.6%) and signs of hypoxic brain injury (11.8%). Furthermore, cortical SAH, typical and atypical cerebral hematomas, ischemic strokes, and generalized brain edema were documented. All neuroimaging findings occurred in patients who were either intubated or treated by extracorporeal membrane oxygenation (ECMO). Pathological neuroimaging findings seem to be relatively rare in general, but do occur in a substantial proportion of patients with severe COVID-19 disease needing intubation or ECMO [29].

Only a few clinical cases with diffuse cerebral edema in COVID-19 patients have been reported. Van den Enden et al. described a case of massive and rapidly fatal cerebral edema in a 57-year-old patient (without comorbidities) who was admitted to the ICU with severe ARDS due to COVID-19-induced bilateral pneumonia. After 2 weeks at the ICU, with respiratory conditions improving, the patient developed lethal cerebral edema. The absence of histopathological evidence or CSF analysis complicates determination of a certain diagnosis. Therefore, in this case, differential diagnosis includes: (massive) cerebral venous sinus thrombosis, hemorrhagic/necrotizing (viral) encephalitis (and thereby developing reactive cerebral edema), and (massive) vasculitis [30]. Acute fulminant cerebral edema was previously more often reported in children (4 cases of previously healthy children) with COVID-19. It is a recognized phenotype with high mortality both in adults and children usually associated with other viral causes [29] as mentioned above.

According to these findings, cerebral edema in COVID-19 patients may either result from direct viral effects on the brain or secondary effects due to pulmonary disturbances (hypoxia due to COVID-19 pneumonia and ARDS), or from treatment consequences (invasive ventilation, ECMO, or various medications), as well as a combination of these factors.

## References

1. WHO Coronavirus (COVID-19) Dashboard [Internet]. Covid19.who.int. 2021 [cited 2021 Dec 11]. Available from: <https://covid19.who.int/>
2. Bodro M, Compta Y, Sánchez-Valle R. Presentations and mechanisms of CNS disorders related to COVID-19. *Neurol Neuroimmunol Neuroinflamm* 2020; 8(1): e923. <https://doi.org/10.1212/NXI.0000000000000923>
3. Montalvan V, Lee J, Bueso T, De Toledo J, Rivas K. Neurological manifestations of COVID-19 and other coronavirus infections: a systematic review. *Clin Neurol Neurosurg* 2020; 194: 105921. <https://doi.org/10.1016/j.clineuro.2020.105921>
4. Wu Y, Xu X, Chen Z, Duan J, Hashimoto K, Yang L, et al. Nervous system involvement after infection with COVID-19 and other coronaviruses. *Brain Behav Immun* 2020; 87: 18–22. <https://doi.org/10.1016/j.bbi.2020.03.031>
5. Alomari S, Abou-Mrad Z, Bydon A. COVID-19 and the central nervous system. *Clin Neurol Neurosurg* 2020; 198: 106116. <https://doi.org/10.1016/j.clineuro.2020.106116>
6. Mao L, Jin H, Wang M, Hu Y, Chen S, He Q, et al. Neurologic manifestations of hospitalized patients with coronavirus disease 2019 in Wuhan, China. *JAMA Neurol* 2020; 77(6): 683–90. <https://doi.org/10.1001/jamaneurol.2020.1127>
7. Rahman J, Muralidharan A, Quazi S, Saleem H, Khan S. Neurological and psychological effects of coronavirus (COVID-19): an overview of the current era pandemic. *Cureus* 2020; 12(6): e8460. <https://doi.org/10.7759/cureus.8460>
8. Soltani Zangbar H, Gotji A, Ghadiri T. A review on the neurological manifestations of COVID-19 infection: a mechanistic view. *Mol Neurobiol* 2020; 58(2): 536–49. <https://doi.org/10.1007/s12035-020-02149-0>
9. DosSantos M, Devalle S, Aran V, Capra D, Roque NR, Coelho-Aguiar JdR, et al. Neuromechanisms of SARS-CoV-2: a review. *Front Neuroanat* 2020; 14: 37. <https://doi.org/10.3389/fnana.2020.00037>
10. Nagu P, Parashar A, Behl T, Mehta V. CNS implications of COVID-19: a comprehensive review. *Rev Neurosci* 2020; 32(2): 219–34. <https://doi.org/10.1515/revneuro-2020-0070>
11. Fotuhi M, Mian A, Meysami S, Raji C. Neurobiology of COVID-19. *J Alzheimer's Dis* 2020; 76(1): 3–19. <https://doi.org/10.3233/JAD-200581>
12. Wang L, Shen Y, Li M, Chuang H, Ye Y, Zhao H, et al. Clinical manifestations and evidence of neurological involvement in 2019 novel coronavirus SARS-CoV-2: a systematic review and meta-analysis. *J Neurol* 2020; 267(10): 2777–89. <https://doi.org/10.1007/s00415-020-09974-2>
13. Flowers LO. COVID-19 and the cytokine storm. *Biomed J Sci Tech Res* 2020; 29(4): 22644–7. <https://doi.org/10.26717/BJSTR.2020.29.004833>
14. Mahmudpour M, Roozbeh J, Keshavarz M, Farrokhi S, Nabipour I. COVID-19 cytokine storm: the anger of inflammation. *Cytokine* 2020; 133: 155151. <https://doi.org/10.1016/j.cyto.2020.155151>
15. Huang C, Wang Y, Li X, Ren L, Zhao J, Hu Y, et al. Clinical features of patients infected with 2019 novel coronavirus in Wuhan, China. *Lancet* 2020; 395(10223): 497–506. [https://doi.org/10.1016/S0140-6736\(20\)30183-5](https://doi.org/10.1016/S0140-6736(20)30183-5)
16. Yu H, Sun T, Feng J. Complications and pathophysiology of COVID-19 in the nervous system. *Front Neurol* 2020; 11: 573421. <https://doi.org/10.3389/fneur.2020.573421>
17. Abboud H, Abboud F, Kharbouch H, Arkha Y, El Abbadi N, El Ouahabi A. COVID-19 and SARS-Cov-2 infection: pathophysiology and clinical effects on the nervous system. *World Neurosurg* 2020; 140: 49–53. <https://doi.org/10.1016/j.wneu.2020.05.193>
18. Li Y, Li M, Wang M, Zhou Y, Chang J, Xian Y, et al. Acute cerebrovascular disease following COVID-19: a single center, retrospective, observational study. *Stroke Vasc Neurol* 2020; 5(3): 279–84. <https://doi.org/10.1136/svn-2020-000431>
19. Sharifi-Razavi A, Karimi N, Rouhani N. COVID-19 and intracerebral haemorrhage: causative or coincidental? *New Microbes New Infect* 2020; 35: 100669. <https://doi.org/10.1016/j.nmni.2020.100669>

20. Wang D, Hu B, Hu C, Zhu F, Liu X, Zhang J, et al. Clinical characteristics of 138 hospitalized patients with 2019 novel coronavirus-infected pneumonia in Wuhan, China. *JAMA* 2020; 323(11): 1061–9. <https://doi.org/10.1001/jama.2020.1585>
21. Sharifian-Dorche M, Huot P, Oshero M, Wen D, Saveriano A, Giacomini P, et al. Neurological complications of coronavirus infection; a comparative review and lessons learned during the COVID-19 pandemic. *J Neurol Sci* 2020; 417: 117085. <https://doi.org/10.1016/j.jns.2020.117085>
22. Princiotta Cariddi L, Tabae Damavandi P, Carimati F, Banfi P, Clemenzi A, Marelli M, et al. Reversible encephalopathy syndrome (PRES) in a COVID-19 patient. *J Neurol* 2020; 267(11): 3157–60. <https://doi.org/10.1007/s00415-020-10001-7>
23. Ladopoulos T, Zand R, Shahjouei S, Chang J, Motte J, Charles James J, et al. COVID-19: neuroimaging features of a pandemic. *J Neuroimaging* 2021; 31(2): 228–43. <https://doi.org/10.1111/jon.12819>
24. Wang H, Li X, Yan Z, Sun X, Han J, Zhang B. Potential neurological symptoms of COVID-19. *Ther Adv Neurol Disord* 2020; 13: 175628642091783. <https://doi.org/10.1177/1756286420917830>
25. Kai H, Kai M. Interactions of coronaviruses with ACE2, angiotensin II, and RAS inhibitors – lessons from available evidence and insights into COVID-19. *Hypertens Res* 2020; 43(7): 648–54. <https://doi.org/10.1038/s41440-020-0455-8>
26. Cheruiyot I, Sehmi P, Ominde B, Bundi P, Mislani M, Ngure B, et al. Intracranial hemorrhage in coronavirus disease 2019 (COVID-19) patients. *Neurol Sci* 2020; 42(1): 25–33. <https://doi.org/10.1007/s10072-020-04870-z>
27. Sawlani V, Scotton S, Nader K, Jen J, Patel M, Gokani K, et al. COVID-19-related intracranial imaging findings: a large single-centre experience. *Clin Radiol* 2021; 76(2): 108–16. <https://doi.org/10.1016/j.crad.2020.09.002>
28. Vaschetto R, Cena T, Sainaghi P, Meneghetti G, Bazzano S, Vecchio D, et al. Cerebral nervous system vasculitis in a Covid-19 patient with pneumonia. *J Clin Neurosci* 2020; 79: 71–3. <https://doi.org/10.1016/j.jocn.2020.07.032>
29. Büttner L, Bauknecht H, Fleckenstein F, Kahn J, Tietze A, Bohner G, et al. Neuroimaging findings in conjunction with severe COVID-19. *Rofo* 2021; 193(07): 822–9. <https://doi.org/10.1055/a-1345-9784>
30. Van den Enden A, van Gils L, Labout J, van der Jagt M, Moudrou W. Fulminant cerebral edema as a lethal manifestation of COVID-19. *Radiol Case Rep* 2020; 15(9): 1705–8. <https://doi.org/10.1016/j.radcr.2020.06.053>

M. Puodžiūnaitė, R. Sadeckaitė, A. Čikotienė

## ŪMINĖ SMEGENŲ EDEMA: LETALI NEUROLOGINĖ KOMPLIKACIJA, SERGANT COVID-19 INFEKCIJA. KLINIKINIS ATVEJIS IR LITERATŪROS APŽVALGA

### Santrauka

*Įvadas.* Nervų sistemos pažeidimas, sergant COVID-19, gali atsirasti dėl tiesioginio viruso poveikio nervinėms struktūroms arba dėl imuninės sistemos aktyvacijos infekcijos metu. Išskiriamos dažniausios neurologinės komplikacijos, kurios gali išsivystyti esant sunkiai ligos eigai: smegenų edema, neuronų degeneracija, encefalitas, ūminis diseminuojantis encefalomyelitas, *Guillain–Barré* sindromas, *Bickerstaff’* encefalitas, *Miller-Fisher* sindromas, polineuritas, toksinė encefalopatija, insultai.

*Atvejo aprašymas.* Pristatome klinikinį atvejį apie 40 metų paciento COVID-19 infekcijos eigą. Pacientas vartojo tik priešhipertenzinius vaistus, kitų gretutinių ligų neturėjo. Stacionariuotas dėl SARS-CoV-2 sukeltos abipusės pneumonijos, išsivysčiusio ūminio respiracinio distreso sindromo ir atsiradusio deguonies poreikio. Po kelių dienų paciento būklė blogėjo, ryškėjo kvėpavimo funkcijos nepakankamumas ir įvyko traukulių priepuolis su išliekančiu sąmonės sutrikimu. Atlikus galvos smegenų KT tyrimą, buvo rasta subarachnoidinės hemoragijos požymių abipus ir difuzinė smegenų edema, galimai išsivysčiusi dėl sunkios COVID-19 infekcijos eigos.

*Aptarimas.* Nervų sistemos pažeidimą COVID-19 infekcijos metu lemia daug patofiziologinių mechanizmų: ACE-2 receptorių pažeidimas, citokinų audra, hipoksija, kraujo ir smegenų barjero funkcijos sutrikimas ir besivystantis CNS uždegimas. Neurologinių simptomų išreikštumas priklauso nuo COVID-19 infekcijos sunkumo ir gali varijuoti nuo asimptomės infekcijos ir vėliau atsirandančių neurologinių nusiskundimų iki sunkių ir letalių komplikacijų. Mūsų aprašytu atveju staigų CNS pažeidimą su difuzine smegenų edema galimai lėmė SARS-CoV-2 sukeltas kraujagyslių endotelio pažeidimas, citokinų audra ir imuninės sistemos aktyvacijos nulemtas dauginis organų pažeidimas bei hipoksija dėl ryškios plaučių audinio disfunkcijos.

**Raktažodžiai:** SARS-CoV-2, COVID-19, neurologinės komplikacijos, smegenų edema.

Gauta:  
2021 12 21

Primta spaudai:  
2022 03 09